

## LETTERS TO THE EDITOR

### Obsessive-compulsive behaviour and cognitive impairment in a parkinsonian patient after left putaminal lesion

Various studies have reported the occurrence of obsessive-compulsive behaviour in patients with different neurological disorders mostly affecting the basal ganglia.<sup>1,2</sup> Thus the association between obsessive-compulsive behaviour and structural lesions of the basal ganglia has been well documented.<sup>3</sup>

We describe here a parkinsonian patient who, after an ischaemic lesion confined to the left putamen, developed polymorphic obsessive-compulsive behaviour and dementia with clinical features of frontal lobe dysfunction (apathy, grasp reflex, utilisation, and perseverative behaviour).

The patient was a 63 year old, right handed housewife with a four year education. At the age of 37 she developed bilateral upper limb resting tremor and rigidity, followed by progressive slowness of movement and akinesia. She was treated for several years with levodopa and benserazide, which improved her motor performance. The patient presented the typical clinical picture of idiopathic Parkinson's disease.

Regular neurological and neuropsychological follow up did not disclose any sign of cognitive impairment or any behavioural abnormality until July 1991, when she was aged 60. At that time, during a hypertensive episode, the patient had a left hemispheric ischaemic accident, which acutely brought about a temporary severe reduction of spontaneous speech. Until then, insight, judgement, intellect, and effectiveness in performing customary daily activities had been entirely preserved. On admission, she had mutism and a severe parkinsonian syndrome, with akinesia and rigidity, pronounced flexion of the trunk, and mild inconstant resting tremor, more evident in her upper left limb. No other neurological signs were seen. Muscle strength and reflexes were unaffected. Some days after the ischaemic episode, the patient recovered from mutism and started to report obsessive thoughts (fear that her daughter would divorce, that her son would go to jail, etc).

In the subsequent weeks, changes in social conduct and personality and increasing apathy, together with cognitive decline, gradually appeared. In September 1991, the patient began to exhibit different compulsions, such as repetition of sentences and of single words, going up and down the stairs, and putting on and taking off her shoes. At that time, she presented a left sided palmo-mental reflex, bilateral grasp reflex, and utilisation behaviour. The unified Parkinson's disease rating scale motor score in defined "off" conditions was 75 (maximum score 108), indicating severe impairment.

The compulsive verbal iterations gradually became more and more persistent and other compulsive behaviours (coprolalia and aggressive outbursts) also emerged. Since November 1991, the compulsive verbal iterations have occurred daily for about 18-19 hours and disappear only during sleep, making family life exasperating.

Brain MRI in February 1992 disclosed a small area of increased signal intensity in the anterior portion of the left putamen on T2 weighted and proton density images (figure, A). A slight bilateral reduction in size of the substantia nigra pars compacta was also seen. No other structural brain abnormalities were detectable. These findings were unchanged on a follow up MRI one year later. SPECT was performed in April 1992, while the patient was at rest but producing her customary verbal iterations. Statistical analysis was carried out by computing regional cerebral blood flow (rCBF) right to left ratios in 14 regions of interest. SPECT showed a considerable reduction of rCBF in the left frontal cortical regions, and in the basal ganglia and the thalamus of the left hemisphere (figure, B). These findings are in keeping with earlier clinical and SPECT findings showing that a dysfunction of the frontal cortex may result from selective damage to the basal ganglia.<sup>4</sup>

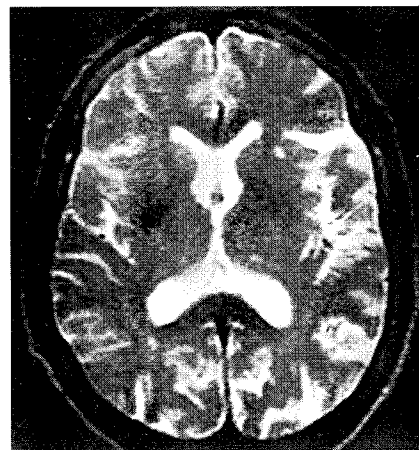
In April 1992, the patient was given a battery of neuropsychological tests,<sup>5</sup> including tasks of verbal and spatial memory (digit and Corsi's span forward and backward, Rey's auditory verbal learning test), tasks sensitive to frontal lobe dysfunction (Wisconsin card sorting test, verbal fluency), Raven's progressive matrices '47, and tasks of constructional apraxia (copy of drawings).

The table shows the results of neuropsychological assessment and the mean scores obtained by 30 healthy controls matched for age and education. The patient was severely impaired on all the cognitive tasks. During the neuropsychological testing, she was uncooperative and unconcerned, showing a remarkable difficulty in paying attention to any task. The patient was continuously and compulsively producing verbal iterations, mainly consisting of repetition of her daughters' names. Perseverative behaviour occurred across several tests, including tasks sensitive to frontal lobe dysfunction. For instance, she produced very many perseverative errors not only on the Wisconsin card sorting test, but also on Raven's progressive matrices. On the second test, she repeatedly pointed to responses in the same spatial position as the previous one.

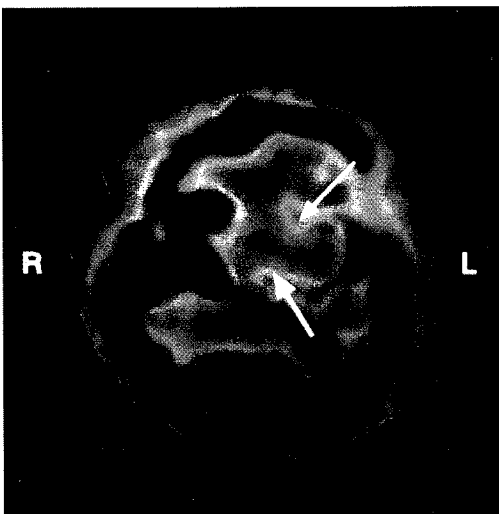
To quantify the severity of her compulsive symptoms, the patient was also rated with the compulsive items (items 6 through 10)

#### Performance on neuropsychological testing

Task	Patient scores	Control scores mean (SD)
Digit span:		
Forward	3	5.1 (0.8)
Backward	2	3.3 (0.9)
Corsi's span:		
Forward	2	4.9 (0.8)
Backward	1	3.7 (1.0)
Rey's auditory verbal learning test:		
Immediate recall (max = 75)	7	35.0 (6.6)
Delayed recall (max = 15)	1	6.7 (2.4)
Wisconsin card sorting test:		
Number of categories (max = 6)	1	4.7 (1.6)
Total errors (max = 128)	75	33.7 (26.3)
Ratio perseverative/total errors	93%	16.0%
Verbal fluency (F, A, S):		
Correct responses	4	21.4 (9.8)
Raven's progressive matrices '47:		
Correct responses (max = 36)	8	21.7 (4.7)
Copying of drawings:		
Correct responses (max = 12)	3	8.7 (1.9)



(A)



(B)

Figure 1 (A) Axial T2 weighted MRI (February 1992): small area of increased signal intensity in the anterior portion of the left putamen. (B) <sup>99</sup>Tc HM-PAO SPECT (April 1992): reduction in regional cerebral blood flow in the frontal regions, the basal ganglia (thin arrow), and the thalamus (thick arrow) of the left hemisphere on axial images.

of the Yale-Brown obsessive compulsive scale.<sup>6</sup> On this scale, the compulsion subtotal score was 18, consistent with a very severe compulsive behaviour (maximum score = 20).

Until now, periodic follow up clinical and neuropsychological examinations have shown no further cognitive decline and no significant change in her obsessive-compulsive behaviour.

To our knowledge, this is the first report on the occurrence of obsessive-compulsive behaviour after a unilateral lesion restricted to the left putamen. The association between neurological disorders and obsessive-compulsive behaviour has been mostly reported in patients with bilateral basal ganglia lesions.<sup>1</sup> Interestingly, Maraganore *et al*<sup>7</sup> described an adolescent boy who, after a small infarction in the right putamen, developed obsessional thoughts and complex motor stereotypies which, however, were not defined as compulsions.

It seems likely that in our patient the putaminal lesion might have played a crucial part in the determinism of obsessive-compulsive behaviour. It has already been shown that focal lesions of the basal ganglia them-

selves may be sufficient to give rise to obsessive-compulsive behaviour.<sup>3</sup> The behavioural symptoms appeared in our patient after an interval of days (obsessions) to weeks (compulsions, apathy) after the putaminal stroke and progressed over subsequent months. Likewise, patients have been described who presented obsessive-compulsive behaviour or "psychic akinesia" (apathy, lack of motivation) after a period varying from days to years after basal ganglia lesions, often with a progressive worsening over time in the initial phase.<sup>2,4,7</sup> The behavioural changes in our patient occurred about 23 years after the onset of Parkinson's disease. Interestingly, although Parkinson's disease is one of the most common neurological disorders affecting the basal ganglia, reports concerning the occurrence of obsessive-compulsive behaviour in Parkinson's disease are surprisingly scanty.<sup>1</sup>

Neuropsychological examination disclosed in this patient a widespread cognitive impairment, with a severely reduced capacity to control attentional resources.

In our patient, compulsive verbal iterations could contribute to her marked breakdown of attentional control, which in turn might partially account for her poor cognitive performance. In dual task paradigms when a secondary task (for example, counting from 1 to 5 repeatedly) is performed concurrently with the task of interest (primary task), performance on one or both tasks will deteriorate if the processing demands of the two tasks exceed the available attentional resources. In this patient, the incessant verbal iterations might act as a sort of articulatory suppression "secondary" task that, during various "primary" cognitive tasks, could interfere with the operation of a limited capacity processing system, such as the supervisory attentional system or the central executive component of the working memory model.

The putamen receives projections from the supplementary motor area, and, in turn, projects back to this area through the internal segment of the globus pallidus and the nucleus ventralis lateralis of the thalamus. Because the left supplementary motor area seems to be involved in motor planning of speech,<sup>8</sup> the association in our patient between obsessive-compulsive behaviour mainly characterised by verbal iterations and a dysfunction in the basal ganglia-frontal loop system in the dominant hemisphere for language is of interest.

A DANIELE  
P BARTOLOMEO  
E CASSETTA  
AR BENTIVOGLIO  
G GAINOTTI  
A ALBANESE  
Istituto di Neurologia,  
Università Cattolica del Sacro Cuore,  
Roma, Italy  
B PARTOLOMEO  
INSERM, Unité 324, Paris, France

Correspondence to: Dr Alberto Albanese, Istituto di Neurologia, Università Cattolica, Largo A Gemelli, 81-00168 Roma, Italy.

- Hymas N, Lees A, Bolton D, Epps K, Head D. The neurology of obsessional slowness. *Brain* 1991;114:2203-33.
- McGuire PK. The brain in obsessive-compulsive disorder. *J Neurol Neurosurg Psychiatry* 1995;59:457-9.
- Laplane D, Levasseur M, Pillon B, et al. Obsessive-compulsive and other behavioural changes with bilateral basal ganglia lesions. *Brain* 1989;112:699-725.
- Strub RL. Frontal lobe syndrome in a patient with bilateral globus pallidus lesions. *Arch Neurol* 1989;46:1024-7.

- Caltagirone C, Gainotti G, Masullo C, Miceli G. Validity of some neuropsychological tests in the assessment of mental deterioration. *Acta Psychiatr Scand* 1979;60:50-6.
- Goodman WK, Price LK, Rasmussen SA, et al. The Yale-Brown obsessive-compulsive scale. I. Development, use, and reliability. *Arch Gen Psychiatry* 1989;46:1006-11.
- Maraganore DM, Lees AJ, Marsden CD. Complex stereotypes after right putaminal infarction: a case report. *Mov Disord* 1991;6:358-61.
- Petersen SE, Fox PT, Posner MI, Mintun M, Raichle ME. Positron emission tomographic studies of the cortical anatomy of single-word processing. *Nature* 1988;331:585-9.

### Down's syndrome and Parkinson's disease

Almost all patients aged over 40 with Down's syndrome develop dementia consistent with Alzheimer's disease with senile plaques and neurofibrillary tangles. There is some overlap between Alzheimer's and Parkinson's disease, with severe dementia occurring in about 15% of patients with Parkinson's disease. Rigidity and, less commonly, other parkinsonian features occur in some patients with Alzheimer's disease. The relatively new concept of Lewy body dementia has created even greater problems in delineating the two entities. A pathological-anatomical link between the genetically determined chromosomal aberration Down's syndrome and Parkinson's disease would be an argument in favour of genetic influences in Parkinson's disease, and of shared pathogenetic links between Alzheimer's and Parkinson's diseases. The pathological hallmarks of Parkinson's disease are Lewy bodies, with severe neuronal loss in the ventrolateral tier of the pars compacta of the substantia nigra. Pathological studies have suggested that cortical neurofibrillary tangles and neuritic plaques are associated more often with Lewy bodies in the brain stem than could be explained on the basis of chance.<sup>1</sup> However, in an extensive search for Lewy bodies in 121 patients with Alzheimer's disease and 273 controls without Parkinson's disease, Gibb *et al* were not able to establish such an association.<sup>2</sup> There are some reports of parkinsonian signs in Down's syndrome,<sup>3</sup> and of improvement after treatment with levodopa.<sup>4,5</sup> Bodhiredy *et al*<sup>6</sup> described a patient with Down's syndrome with diffuse Lewy body disease and Alzheimer's disease. Raghavan *et al*<sup>7</sup> found two patients with nigral Lewy bodies but no cell loss in 23 patients with Down's syndrome. They argued that the presence of Lewy bodies in two out of 23 cases (8.7%) in this age group (with the expectation of incidental Lewy bodies being less than 1%) is probably not coincidental. However, in 14 cases of Down's syndrome, Gibb *et al* found no nigral Lewy bodies.<sup>8</sup>

We examined haematoxylin and eosin stained sections from the substantia nigra of 27 patients with Down's syndrome, aged 25 to 70, with a mean age of 47.8 years. Ten patients were aged between 50 and 59, five between 60 and 69, and one patient was 70 years old. The clinical diagnosis of Alzheimer's disease is difficult to ascertain in mentally retarded patients. It was based on above all the appearance of memory deficits but also, although usually later, increased orientation difficulties. Alzheimer's disease was suspected in 21 of our 22 patients over 30 years of age. No Lewy bodies were found, but in all cases of clinically suspected Alzheimer's disease nigral neurons contain-

ing tangles were easily identified. One patient, a woman, who died aged 56, was examined one year before death, at a neurological department. She was judged to be parkinsonian with rigidity and given medication (benserazid/levodopa). At postmortem no Lewy bodies were found in the nigra; there was nigral cell loss but not to the degree usually seen in Parkinson's disease.

The frequency of incidental Lewy bodies between the sixth and ninth decade has been reported by Gibb and Lees<sup>2</sup>: after compilation of five other studies, the percentage in the age group 50 to 59 was 1.8% and between 60 to 69 it was 10.7%. For the whole group, aged between 50 and 69 Lewy bodies were found in 32 out of 437 patients (7.3%).

As there were no Lewy bodies in the tissues examined, our study suggests that there is no link between Parkinson's disease and Down's syndrome. This is contrary to the opinion of Raghavan *et al*, but agrees with the findings of Gibb and Lees. A compilation of these two studies with our own, only including patients aged between 50 and 69, gives two patients out of 46 (4.3%) with Lewy bodies. This result, compared with 7.3% among controls, makes it highly unlikely that there is an increased frequency of Lewy bodies in patients with Down's syndrome.

A HESTNES

SE DANIEL

AJ LEES

Parkinson's Disease Society Brain Research Centre  
(Brain Bank), Institute of Neurology, 1 Wakefield  
Street, London WC1N 1PJ, UK

A HESTNES

Neurologisk afdeling, Vestfold sentralsykehus, 3100

Tønsberg, Norway

A BRUN

Department of Pathology and Cytology, University  
Hospital, Lund, Sweden

SE DANIEL

University Department of Neuropathology

AJ LEES

University Department of Clinical Neurology, Institute  
of Neurology, Queen Square, London WC1N 3BG,  
UK

Correspondence to: Dr A Hestnes, Neurologisk afdeling, Vestfold sentralsykehus, 3100 Tønsberg, Norway.

- Boller F, Mizutani T, Roessman U, Gambetti P. Parkinson disease, dementia and Alzheimer's disease: clinicopathological correlations. *Ann Neurol* 1980;7:329-35.
- Gibb WRG, Mountjoy CQ, Mann DMA, Lees AJ. A pathological study of the association between Lewy body disease and Alzheimer's disease. *J Neurol Neurosurg Psychiatry* 1989;52:701-8.
- Viergege P, Ziemens G, Freudenberg M, Piosinski A, Muysers A, Schulze B. Extrapyramidal features in advanced Down's syndrome: clinical evaluation and family history. *J Neurol Neurosurg Psychiatry* 1991;54:34-8.
- Brandel JP, Marconi R, Serdaru M, Vidailhet M, Agid Y. Down's syndrome and Parkinson's disease [letter]. *Neurology* 1994;24:19-20.
- Singer C, Sanchez-Ramos J, Weiner WJ. Levodopa-responsive parkinsonism in a patient with Down's syndrome. *Eur Neurol* 1990;30:247-8.
- Bodhiredy S, Dickson DW, Mattiace L, Weidenheim KM. A case of Down's syndrome with diffuse Lewy body disease and Alzheimer's disease. *Neurology* 1994;44:159-61.
- Raghavan R, Khin-Nu C, Brown A, et al. Detection of Lewy bodies in Trisomy 21 (Down's syndrome). *Can J Neurol Sci* 1993;20:48-51.
- Gibb WRG, Mountjoy CQ, Mann DMA, Lees AJ. The substantia nigra and ventral tegmental area in Alzheimer's disease and Down's syndrome. *J Neurol Neurosurg Psychiatry* 1989;52:193-200.
- Gibb WRG, Lees AJ. The relevance of the Lewy body to the pathogenesis of idiopathic Parkinson's disease. *J Neurol Neurosurg Psychiatry* 1988;51:745-52.